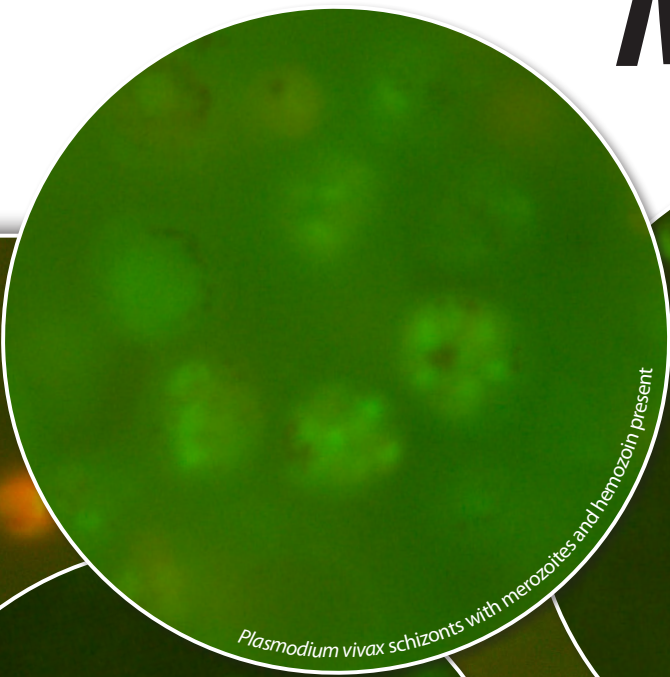




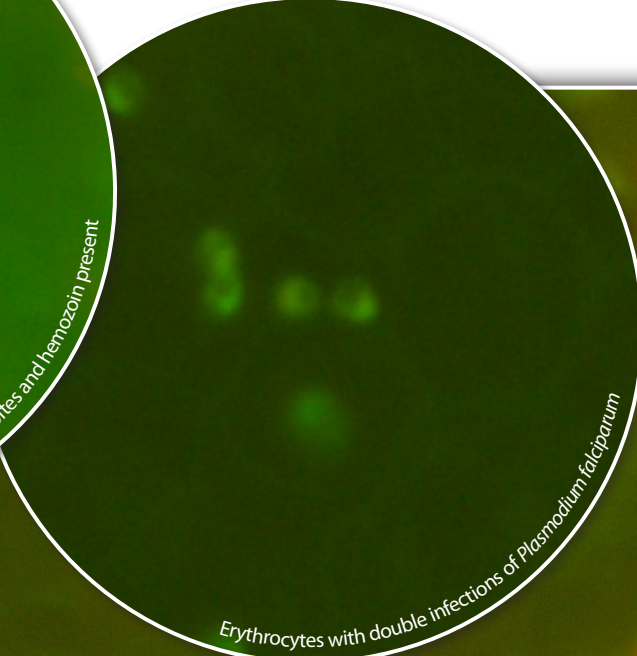
PARAWORLD

PARAWORLD Training Resources

# *Atlas of* **Blood Parasite** *Morphologies*



*Plasmodium vivax* schizonts with merozoites and hemozoin present



Erythrocytes with double infections of *Plasmodium falciparum*



WBC next to RBCs with malaria infections


 **QBC<sup>®</sup> Diagnostics**  
Innovative Solutions for a Healthier World

An aid to guide the microscopist in recognizing the forms of parasites as they appear in the QBC method and to compare them with the conventional blood films for diagnosis, species determination and quantitation of parasitemia.

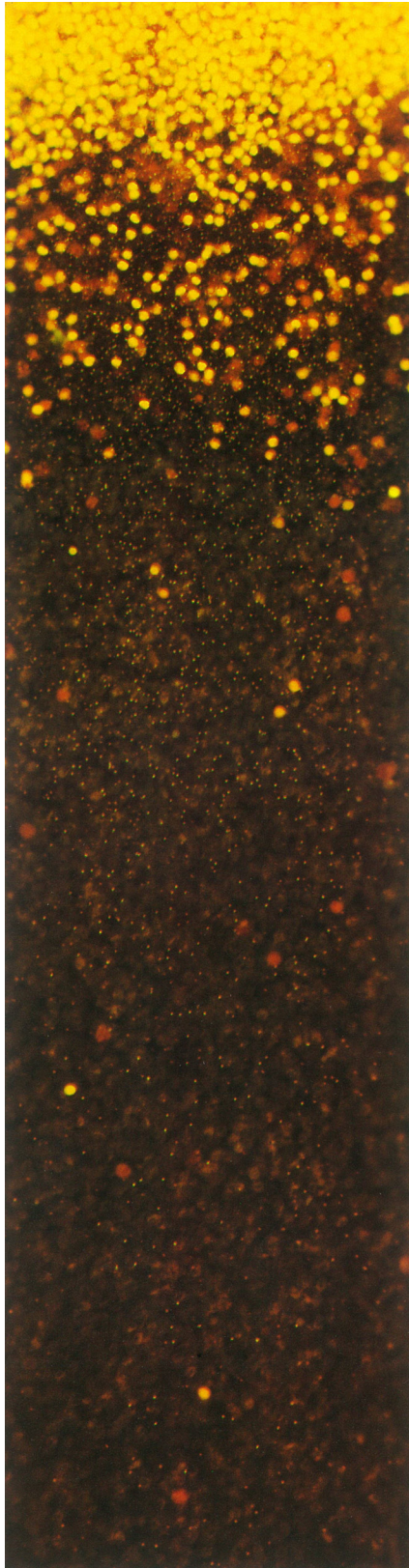
# Page 1: Introduction

**The QBC Tube:** The float occupies the area midpoint between red cells and plasma. Seen enlarged, the three separate layers of the buffy coat are comprised of orange-yellow fluorescing platelets (top), green lymphocytes/monocytes (middle), and yellow granulocytes (bottom). Below the granulocytes is the red blood cell layer (some overlap of RBC's and granulocytes occurs).

Low power micrograph of the granulocyte/red cell interface of a malaria-negative sample of blood.



# Page 2: Concentration Effect



Low power micrograph of the granulocyte/red cell interface of a malaria-positive sample of blood. The small pinpoints of light are individual parasites in the red blood cells. The larger, round fluorescing bodies are granulocytes.

---

Note the decreasing concentration of parasitized red cells as one moves away from the RBC/WBC interface. This micrograph shows the RBC layer 2 mm from the granulocytes.

---

Less than 4 mm from the RBC/WBC interface there are relatively few parasitized RBCs visible due to the concentration effect closer to the interface area.

# Page 3: Technical Assistance

## **Species Differentiation**

The various parasite forms seen in the QBC method make species differentiation possible, as one can see from the preceding and following photo-micrographs. The morphologies closely resemble those seen in the thin film method. However, it is important always to identify species based on specific morphology, relative size and presence or lack of multiple stages of maturity. Occasional artifacts can resemble shapes of parasites but can be disregarded if they lack the other characteristics – see “Artifacts” section.

## **Quantitation**

The QBC method provides an accurate and reproducible method of estimating the relative quantity of parasites in a specimen using the “Plus System”:

+ (1+) = < 1 parasite per QBC field

++ (2+) = 1-10 parasites per QBC field

+++ (3+) = 11-100 parasites per QBC field

++++(4+) = > 100 parasites per QBC field

This system can aid in following the progress of a patient under therapy and in comparing the level of parasitemia from one patient to another.

## **Technical Assistance**

QBC Diagnostics is interested in making available in this atlas all suitable color photo-micrographs of blood parasites detectable by the QBC method—both human and animal. If you wish to submit such photos, please contact QBC Diagnostics or:

QBC Diagnostics  
168 Bradford Drive  
Port Matilda, PA 16870



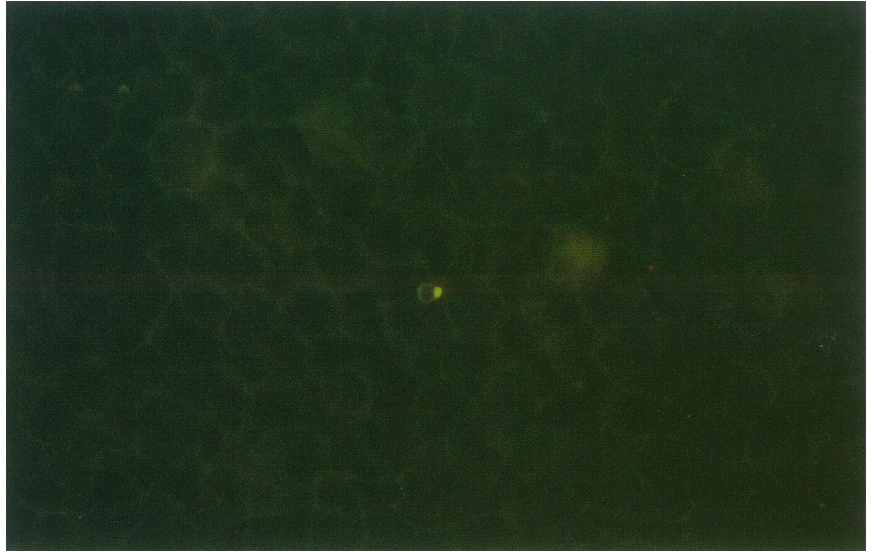
PARAWORLD

PARAWORLD Training Resources

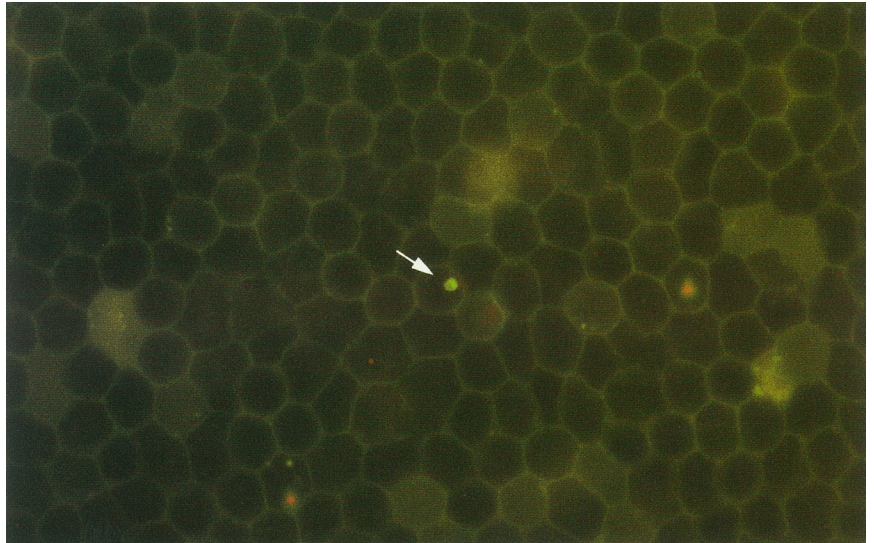
# *Plasmodium falciparum*

# Page 1: *Plasmodium falciparum*

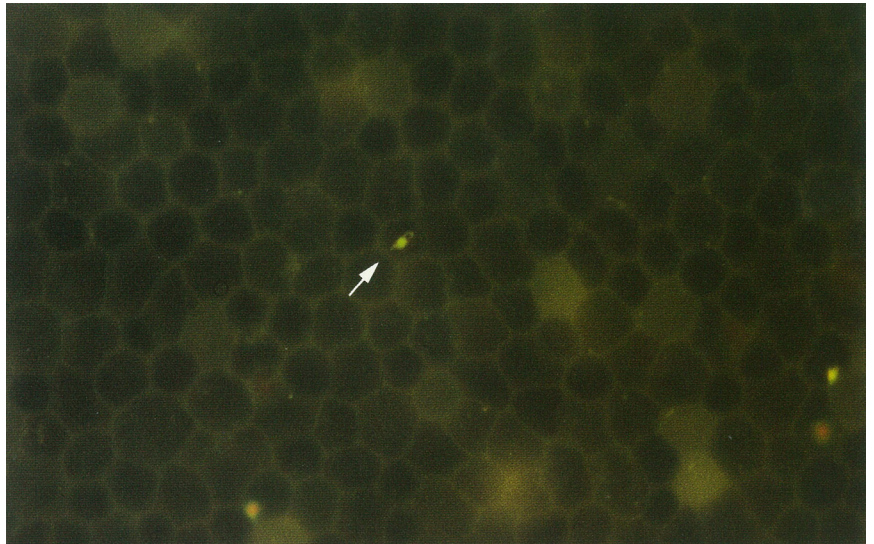
Trophozoite of *P. falciparum*. Note the well-defined, regularly shaped cytoplasm of *P. falciparum*.



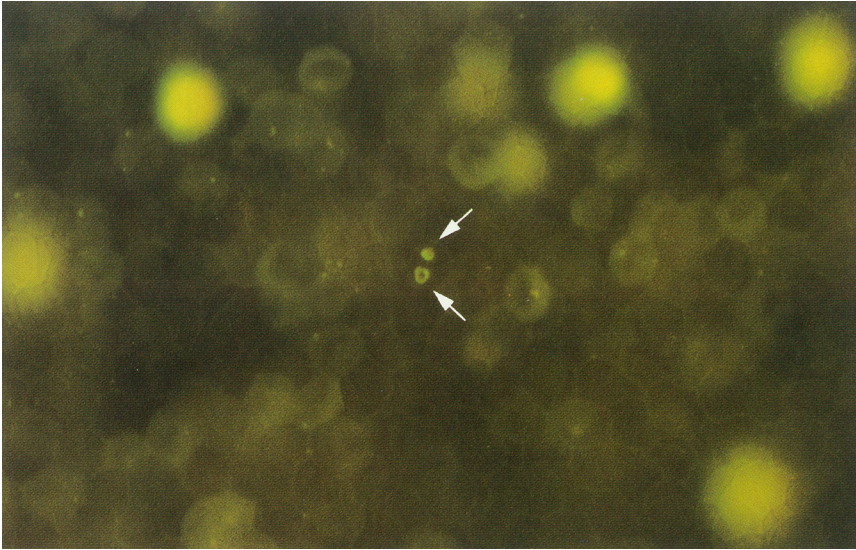
Trophozoite of *P. falciparum* (arrow).



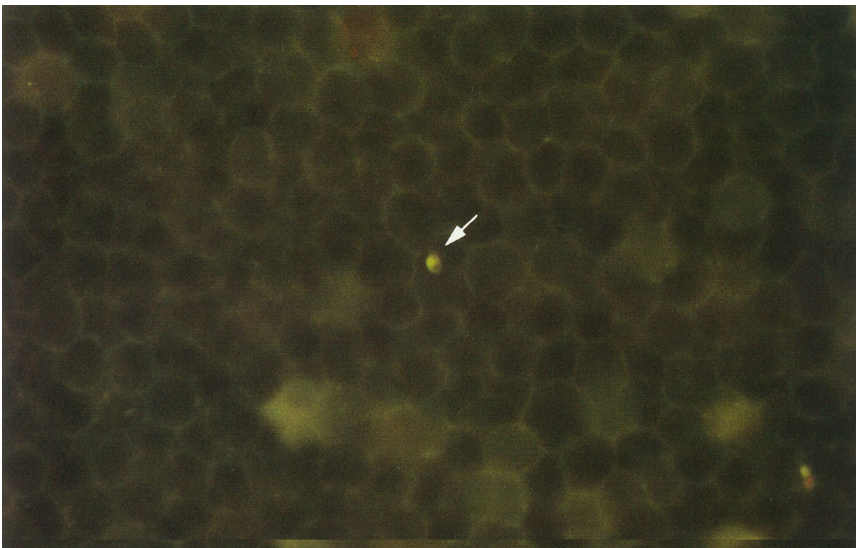
Trophozoite of *P. falciparum* (arrow).



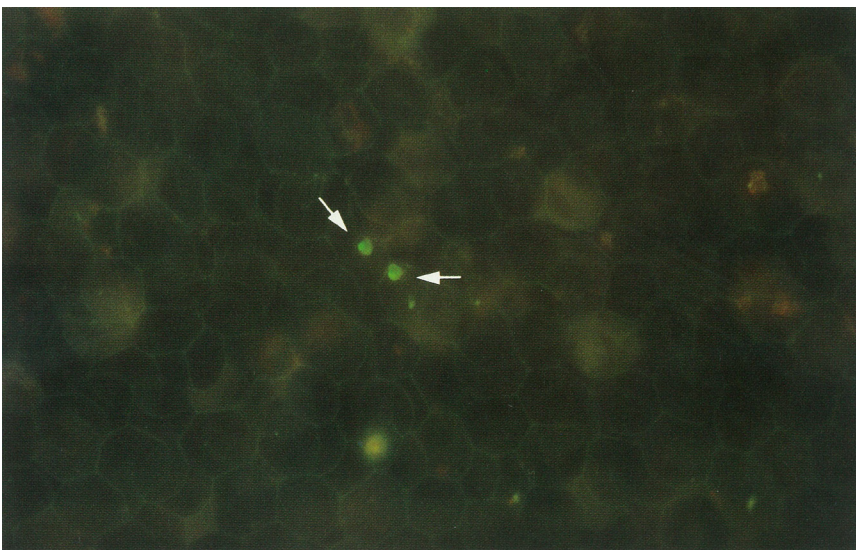
# Page 2: *Plasmodium falciparum*



Two rings of *P. falciparum*.



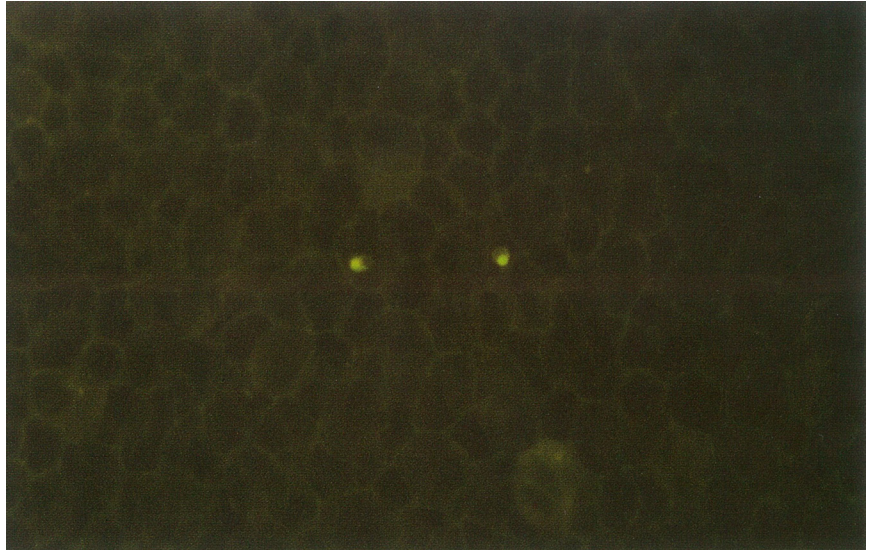
Trophozoite of *P. falciparum*. Note small size and regular shape as compared to *P. vivax*.



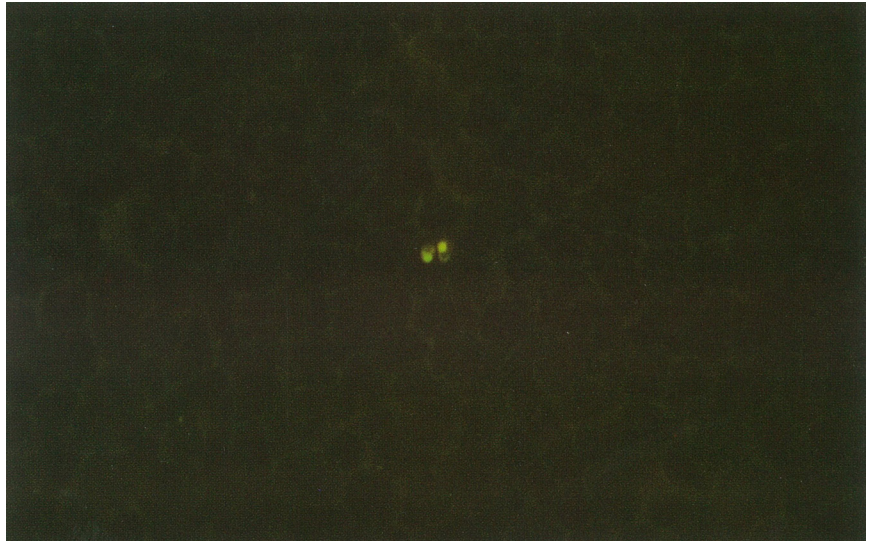Two trophozoites of *P. falciparum* (arrows).

# Page 3: *Plasmodium falciparum*

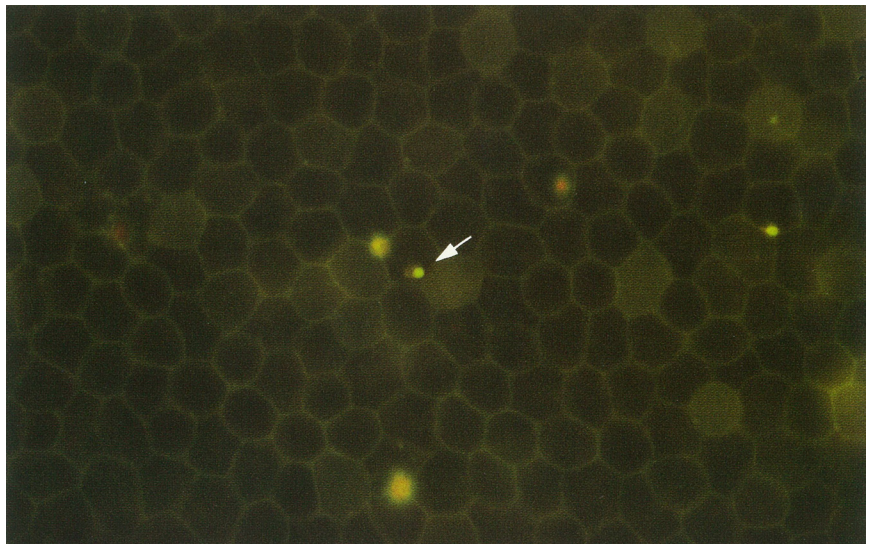
Two trophozoites of *P. falciparum*.



Two rings of *P. falciparum* infecting one red cell.

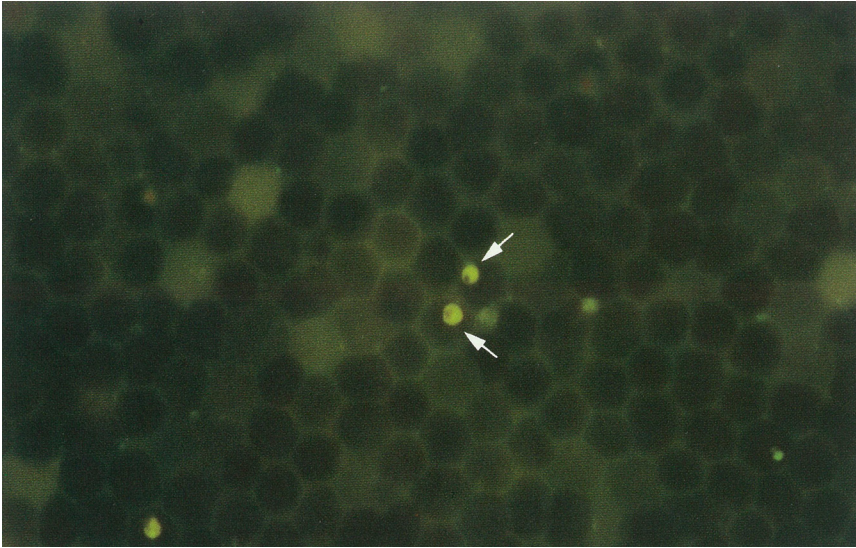


Single trophozoite of *P. falciparum* (arrow).  
Other fluorescing dots do not exhibit characteristic morphology.

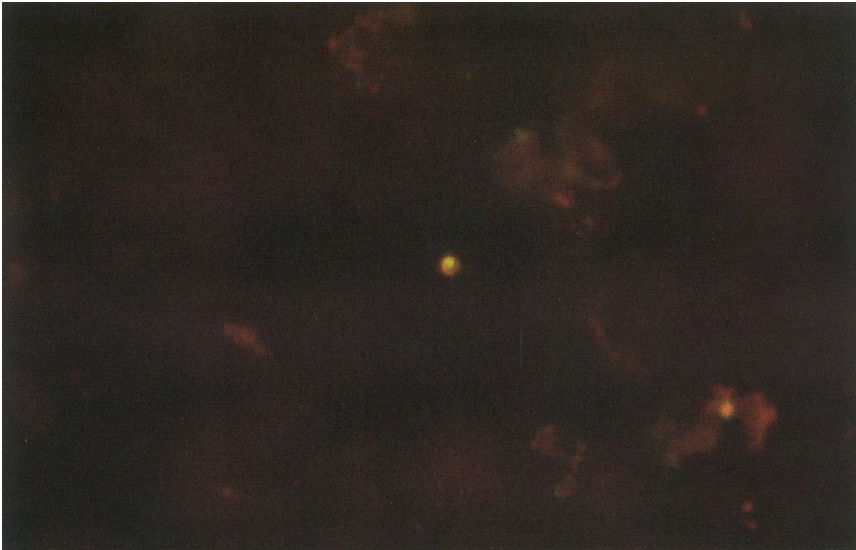




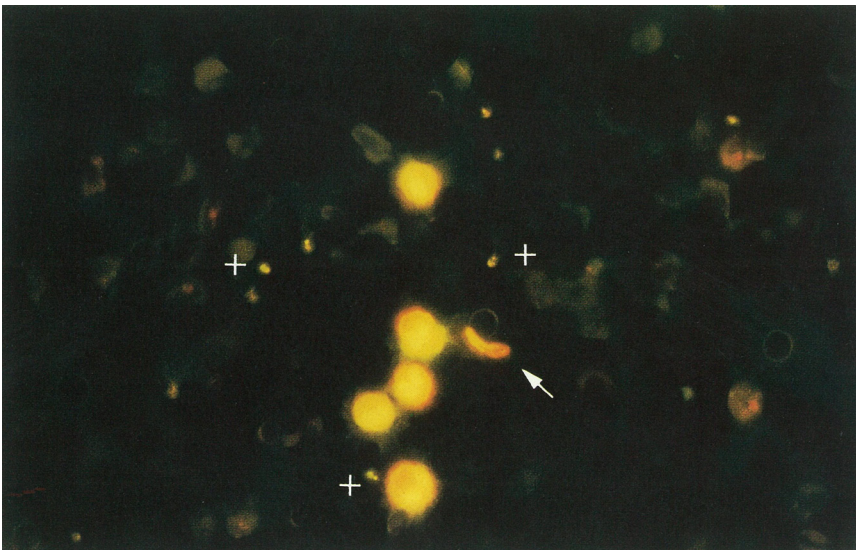
# Page 4: *Plasmodium falciparum*



Two schizonts of *P. falciparum* (arrows) from culture.



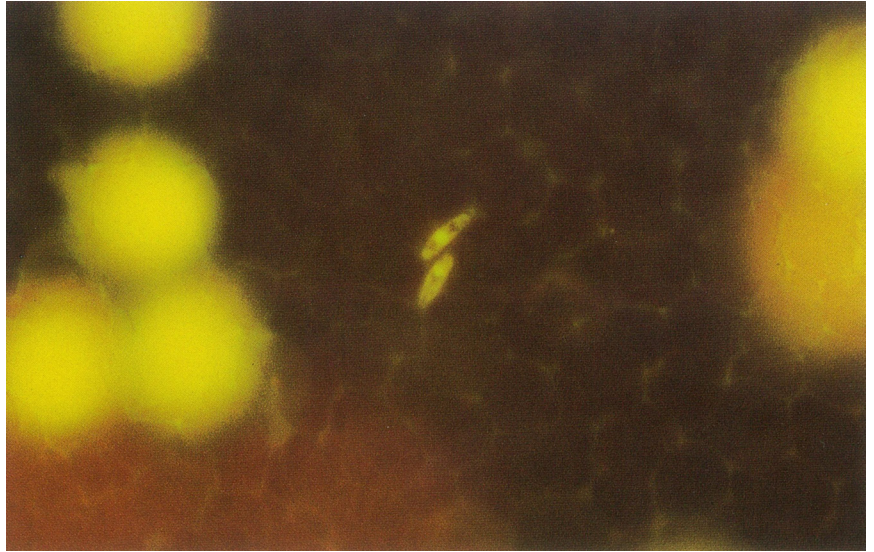
Four day old sample of *P. falciparum*-infected blood. Note trophozoite in the deep red granular background caused by the lysis of some of the red blood cells.



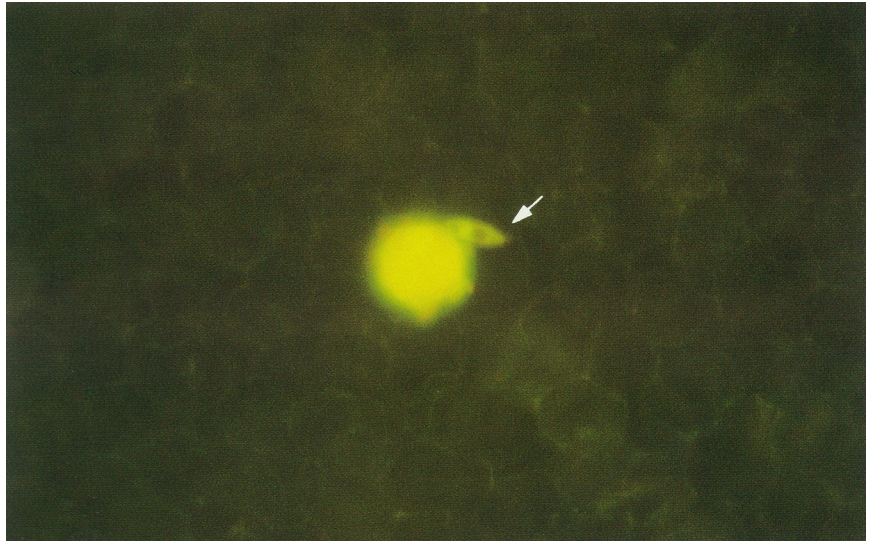Gametocyte (arrow) and numerous trophozoites (crosses) of *P. falciparum*. Note large unmistakable granulocytes.

# Page 5: *Plasmodium falciparum*

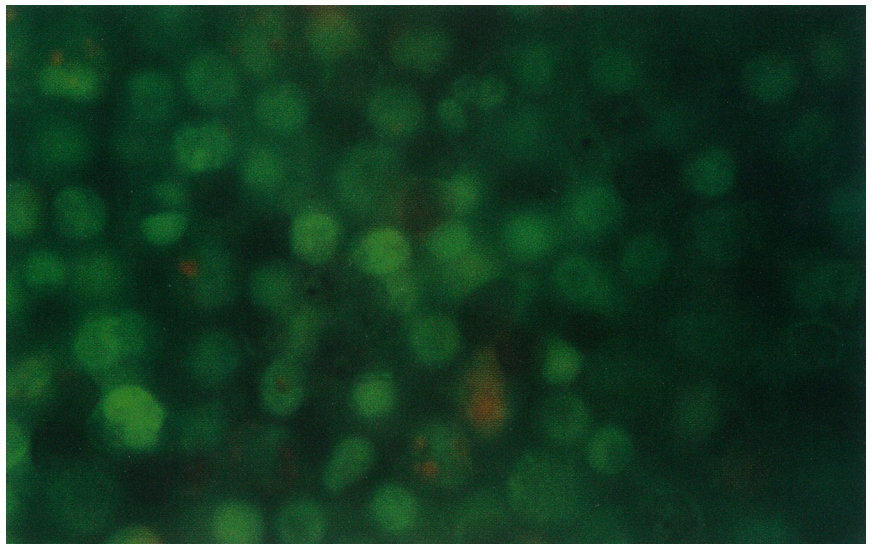
Two gametocytes of *P. falciparum*.



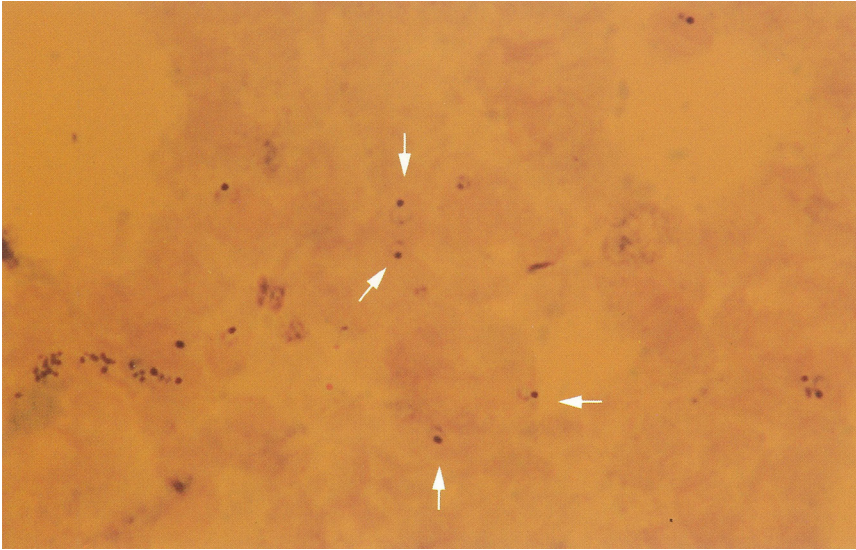
Gametocyte of *P. falciparum* (arrow) near a granulocyte.



Schizonts of *P. falciparum* in the lymphocyte/monocyte layer.



# Page 6: *Plasmodium falciparum*



Typical appearance of a thick film preparation for the diagnosis of malaria trophozoites (arrows).





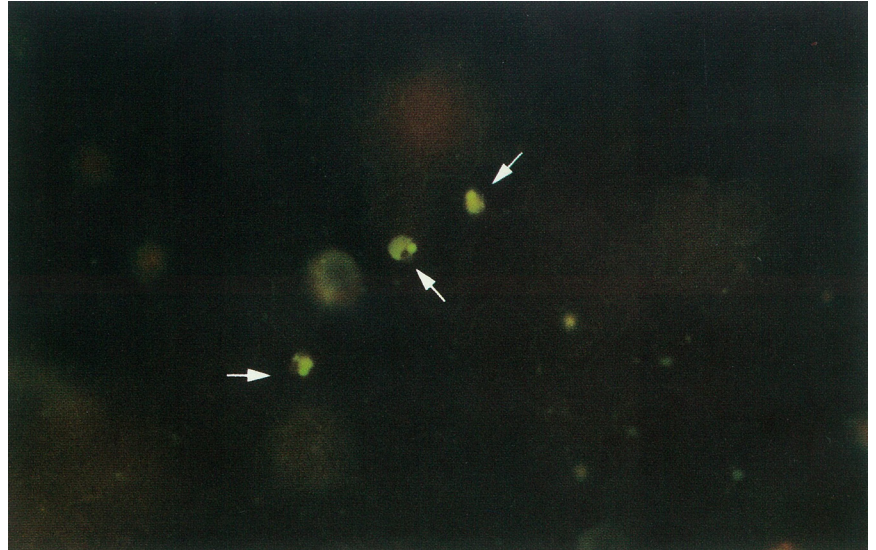
PARAWORLD

PARAWORLD Training Resources

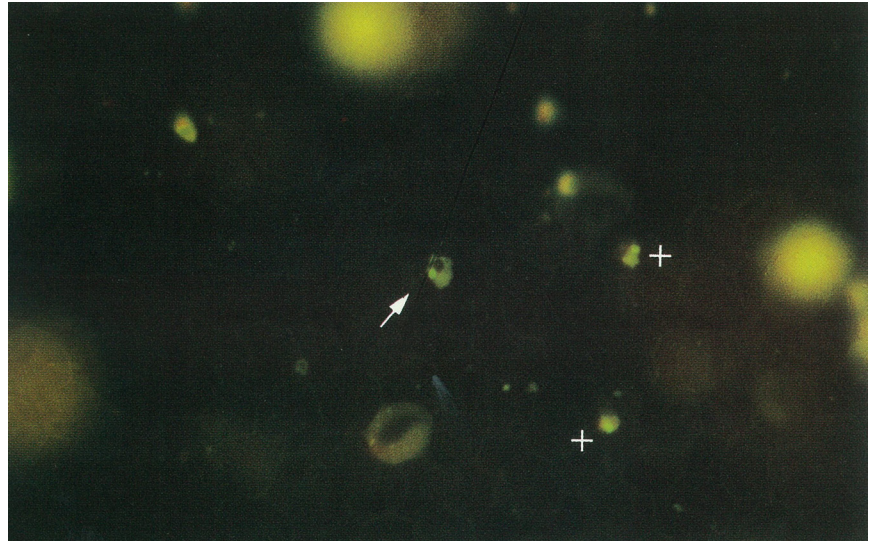
# *Plasmodium vivax*

# Page 1: *Plasmodium vivax*

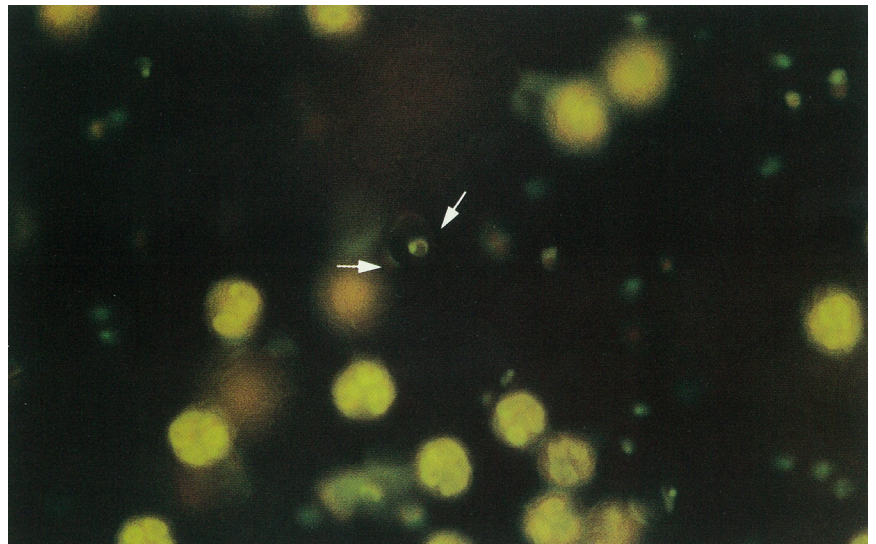
Three trophozoites of *P. vivax* (arrows).

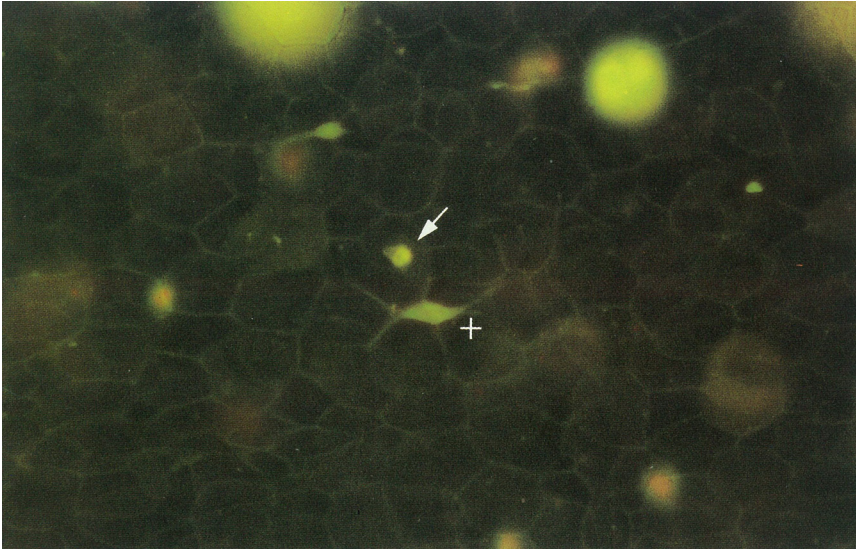


Late (arrow) and early trophozoites (crosses) of *P. vivax*.

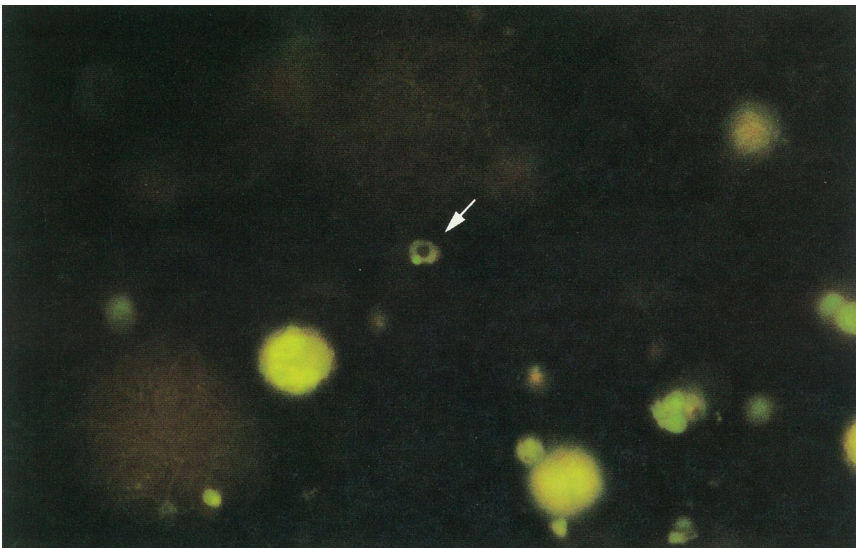


Numerous early trophozoites *P. vivax* scattered among large granulocytes. Note outline of red cell surrounding trophozoite (arrows).

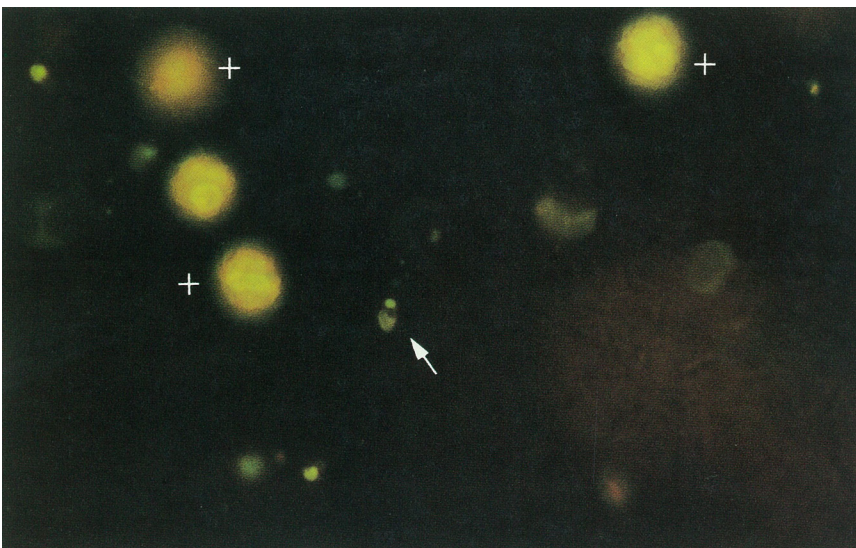




Early trophozoite of *P. vivax* (arrow). Note debris trapped in a shape that might be confused with a *P. falciparum* gametocyte (cross). Although the shape may be distinctive there is an absence of malaria pigment.



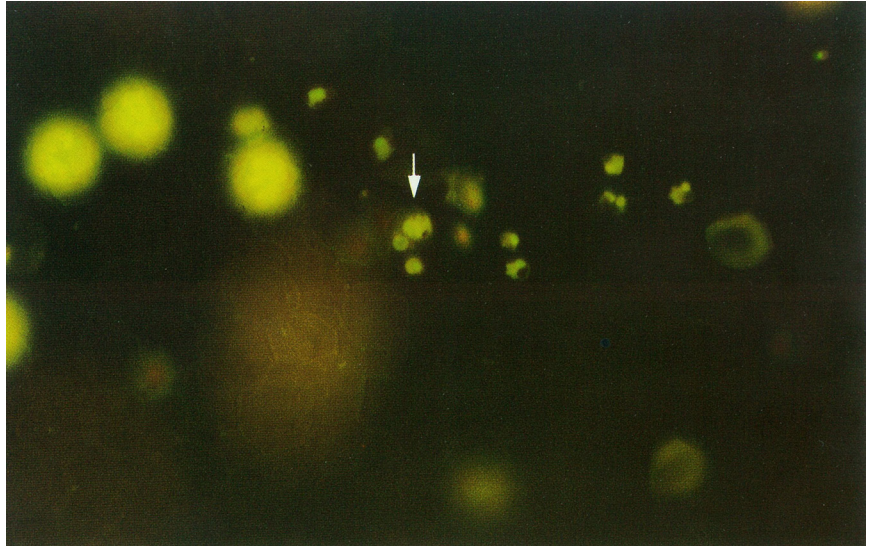
Trophozoite of *P. vivax* (arrow).



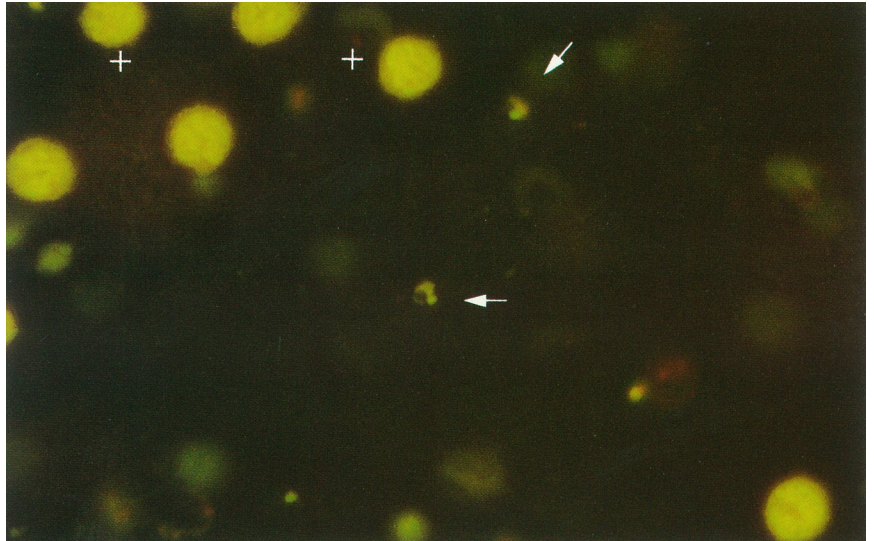
Trophozoite of *P. vivax* (arrow) and granulocytes (crosses).

# Page 3: *Plasmodium vivax*

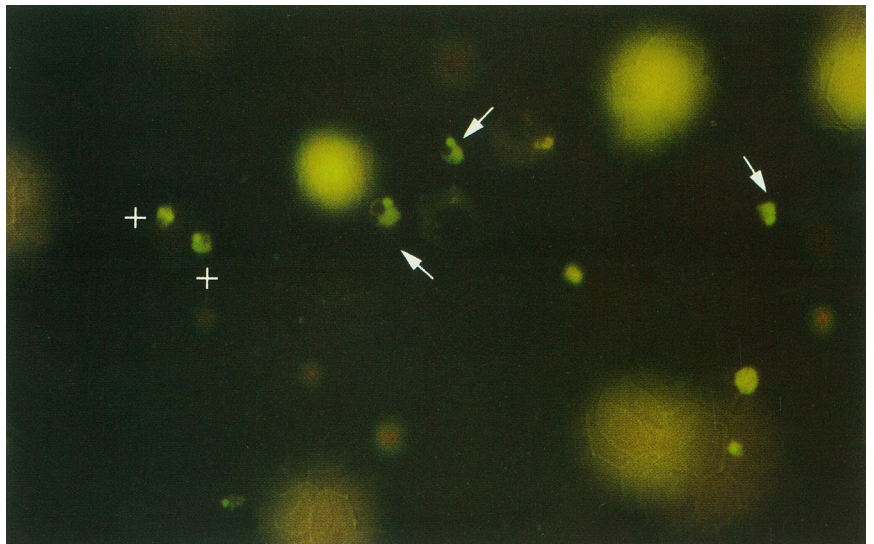
Numerous trophozoites and a schizont of *P. vivax* (arrow).



Trophozoites of *P. vivax* (arrows). Note granulocytes scattered among the field (crosses).

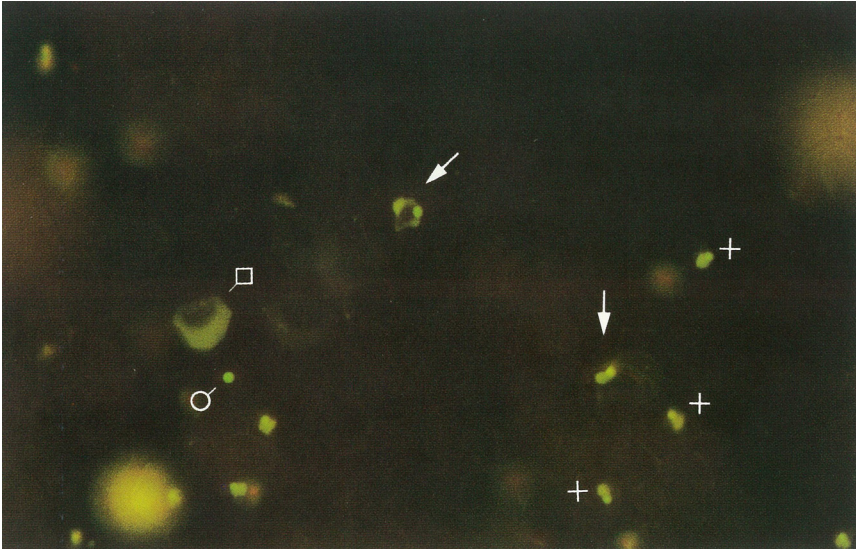


Large late trophozoites (arrow), and a few earlier trophozoites of *P. vivax* (crosses). Note out of focus granulocytes.

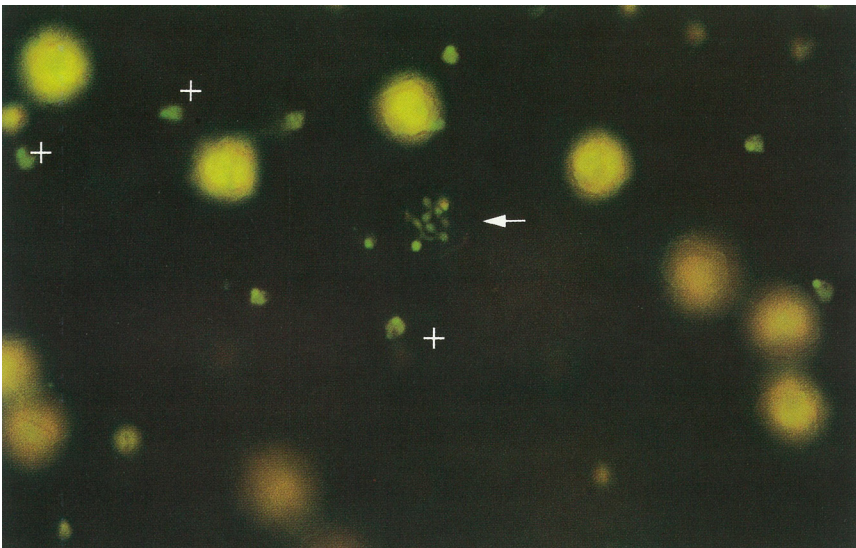




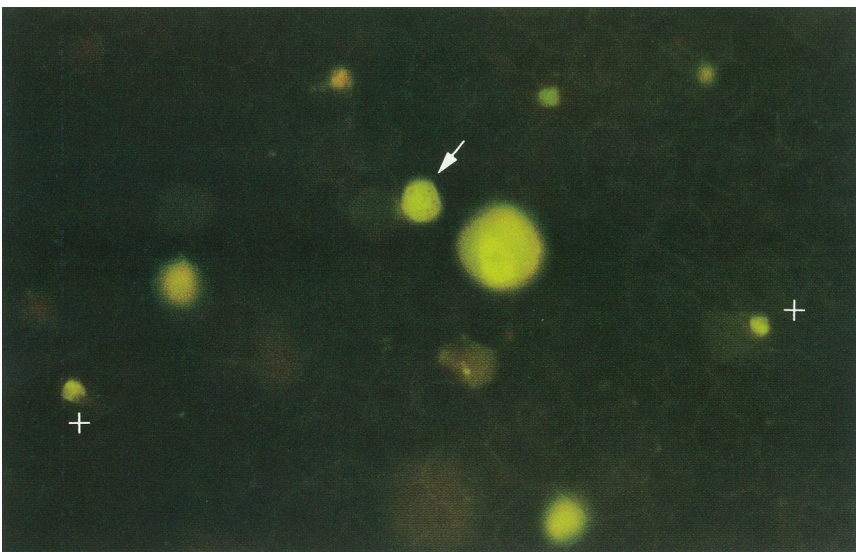
# Page 4: *Plasmodium vivax*



Late trophozoite (arrow) and early trophozoites (crosses) of *P. vivax*. Note red cell ghost (square) that has picked up the stain, and dot (circle) which does not exhibit the characteristic morphology of the *Plasmodia*.



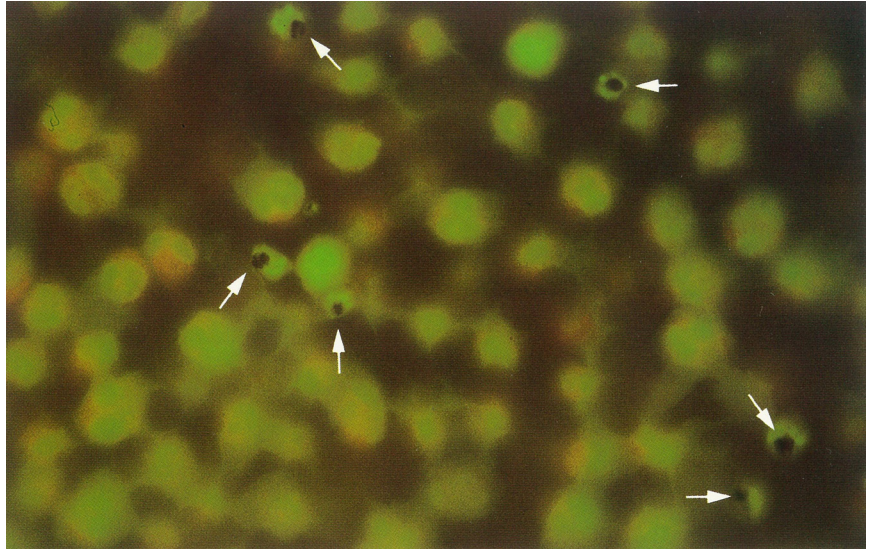
Highly ameboid late trophozoite (arrow) and scattered early trophozoites (crosses) of *P. vivax*.



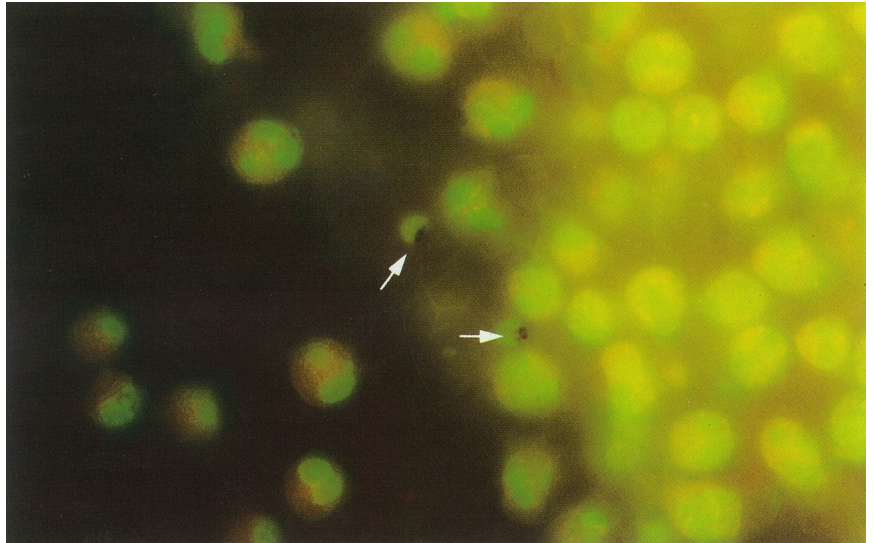
Schizonts of *P. vivax* (note diffuse pigment) next to large granulocyte. Note rings. Trophozoites slightly out of focus (arrows).

# Page 5: *Plasmodium vivax*

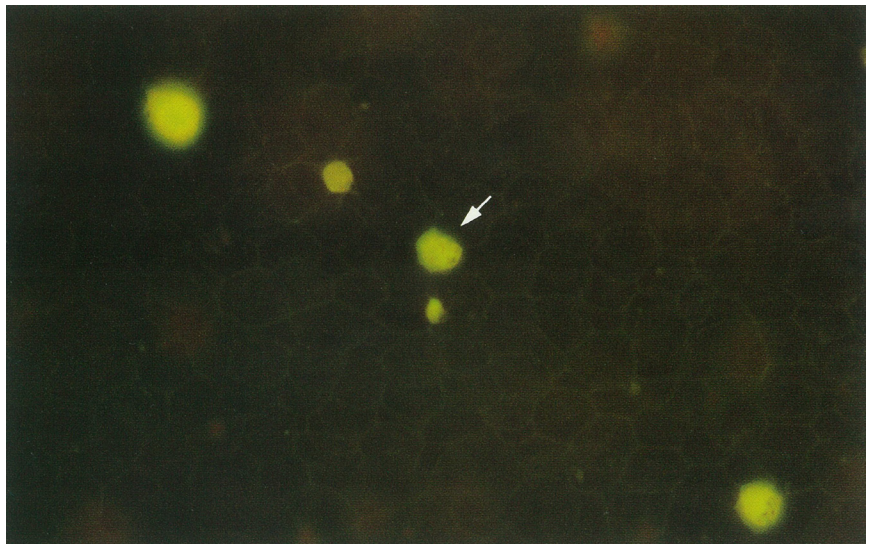
Schizonts of *P. vivax* in granulocyte layer (arrows).



Schizonts of *P. vivax* (arrows) at the red cell/granulocyte interface.



Gametocyte of *P. vivax* (arrow).





PARAWORLD

PARAWORLD Training Resources

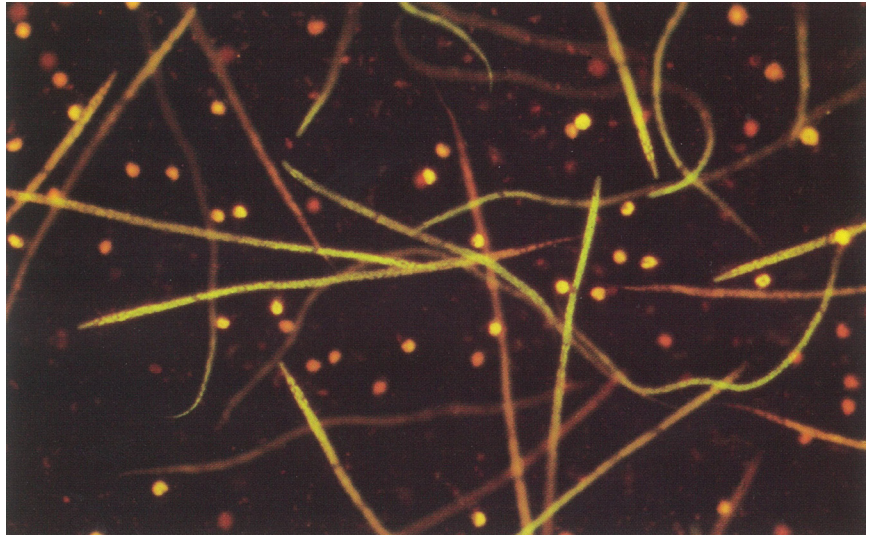
# *Micro Filariae*

# Page 1: Micro *Filariae*


Posterior end of microfilaria of *Dirofilaria immitis*. Note pointed shape of tail and absence of nuclei in caudal space.

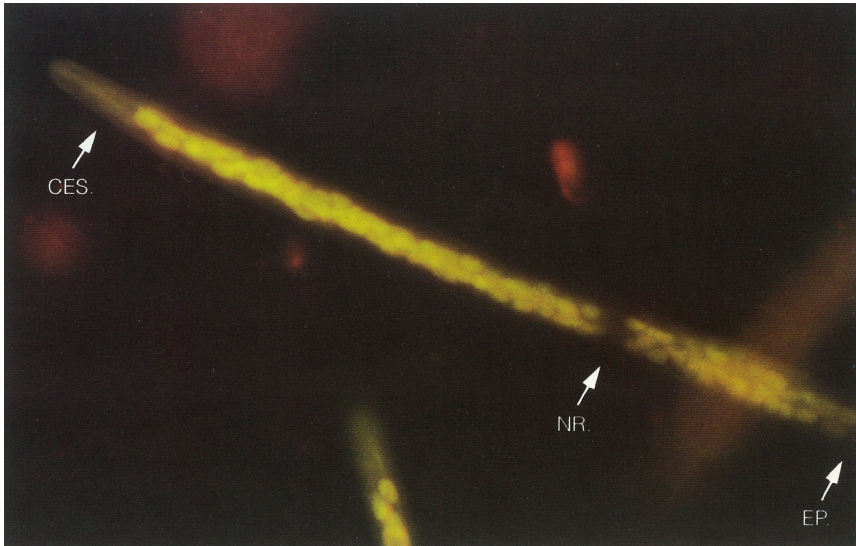


Microfilaria of *Dirofilaria immitis*.



Microfilaria of *Dirofilaria immitis* concentrated near granulocyte / red cell interface. Notice streaming of granulocytes into RBC layer.





Anterior end of microfilaria of *Dirofilaria immitis*. Note absence of sheath. Cephalic space (CES), nerve ring (NR), excretory pore (EP).





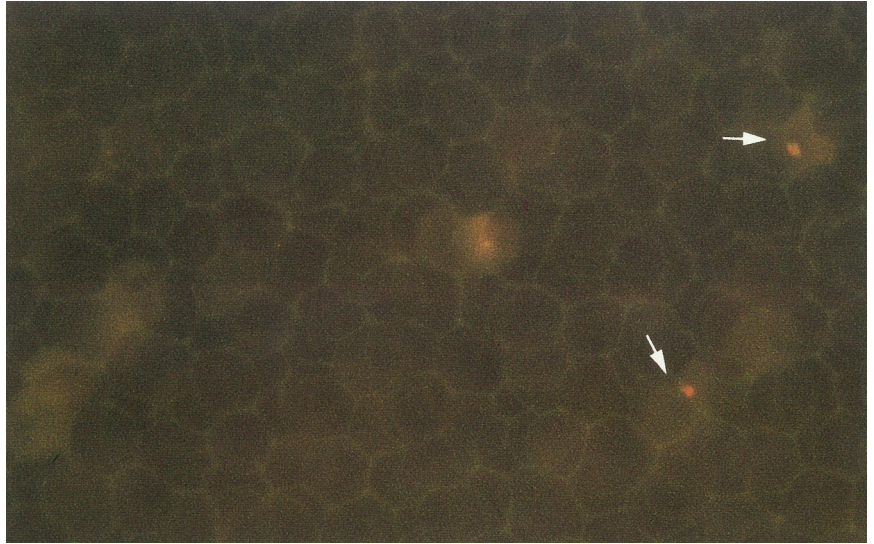
PARAWORLD

PARAWORLD Training Resources

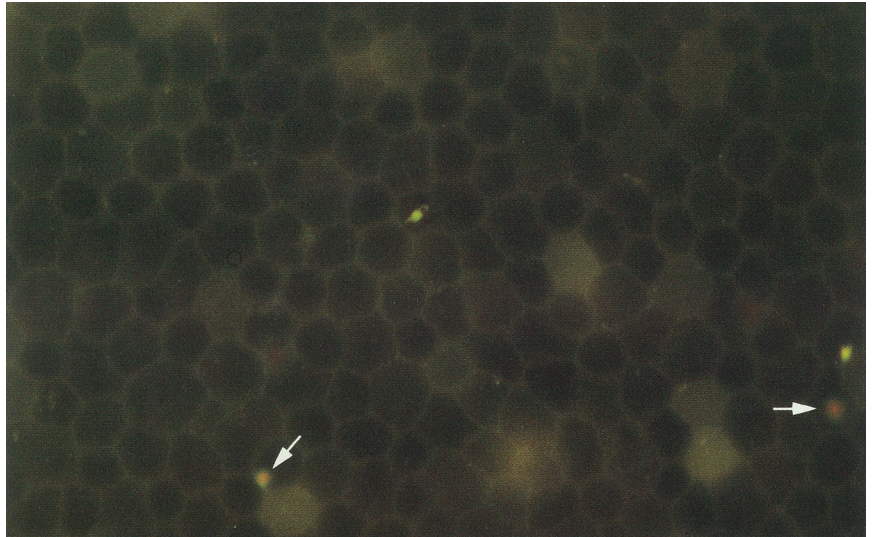
# *Artifacts*

# Page 1: Artifacts

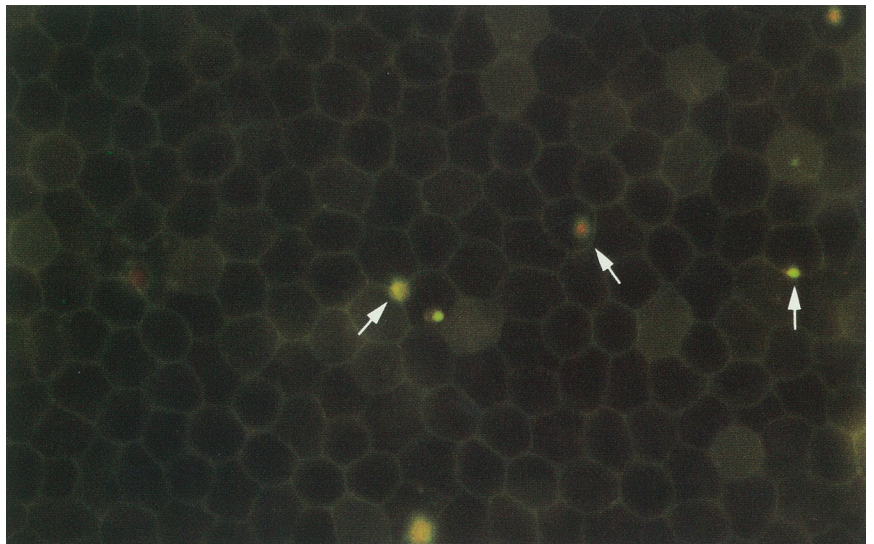
Expanded red cell area of an uninfected sample. Note red color and irregular shape of free clumped hemoglobin (arrows).



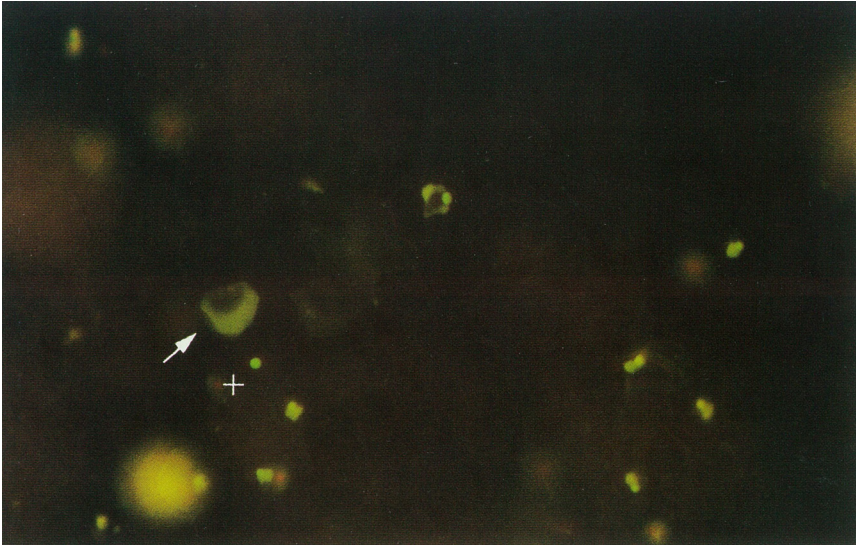
AO stained cell debris (arrows).



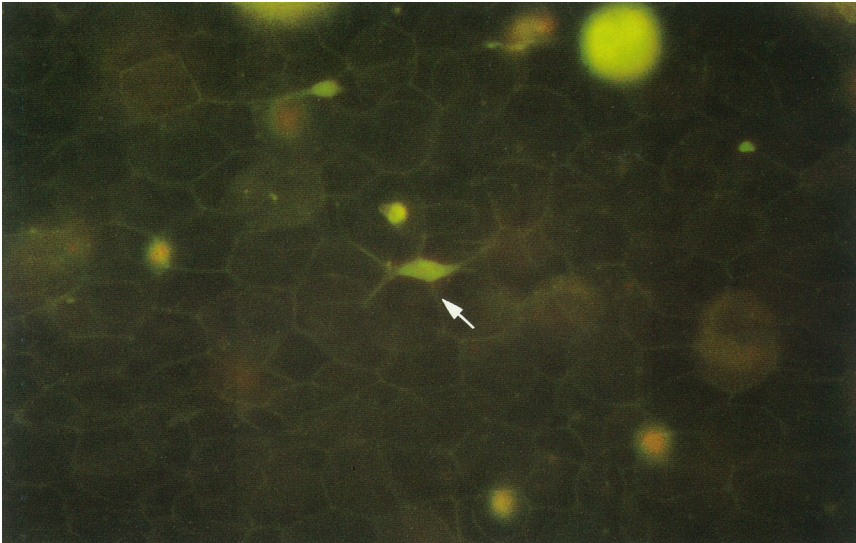
Debris (arrows). No *Plasmodium* morphology is visible.



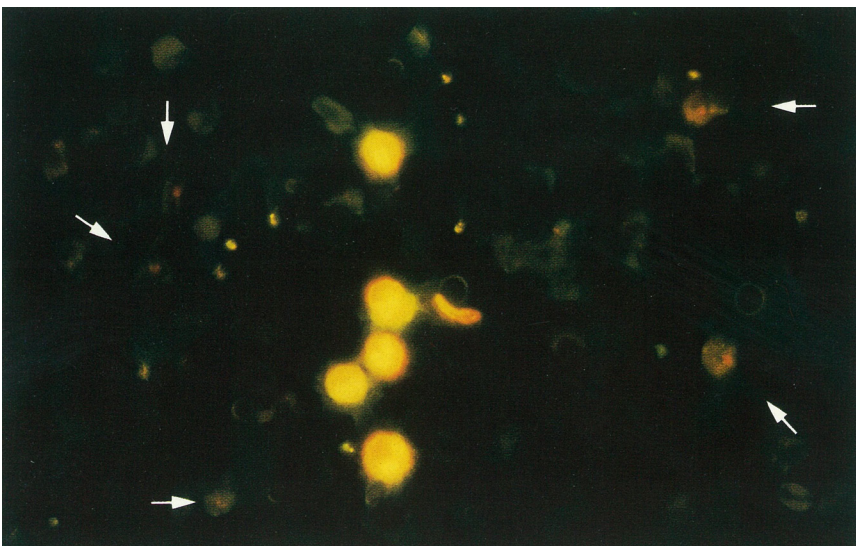




Stained red cell "ghost" (arrow); debris with no *Plasmodium* morphology (cross).



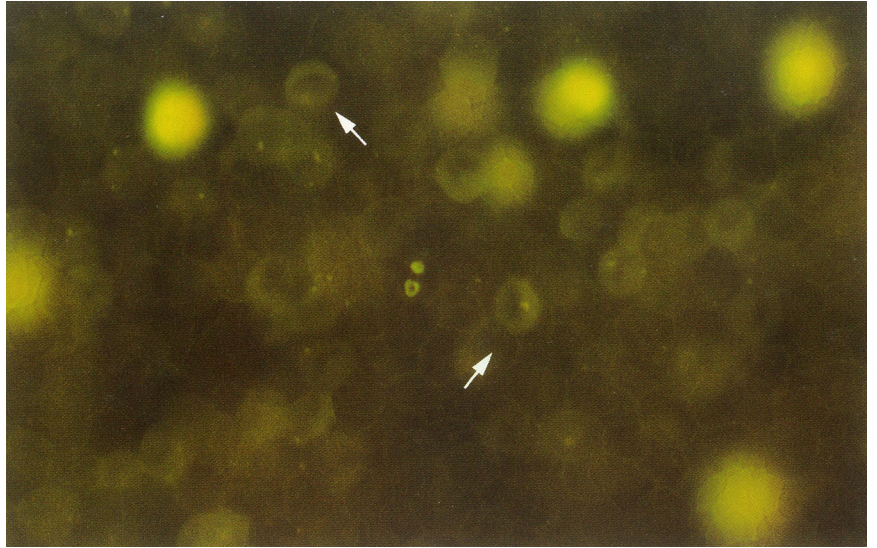
Stained debris suggesting a gametocyte of *P. falciparum*. Lack of malaria pigment indicates it is not a gametocyte.



Appearance of stained red cell debris in an aged specimen (arrows).

# Page 3: Artifacts

Red cell outlines (arrows) and numerous small fluorescent dots.



© Copyright QBC Diagnostics, Inc., 1990, Parts 2010.  
All rights reserved. QBC, QBC Diagnostics, and  
ParaWorld are trademarks of QBC Diagnostics.